



## Consensus of the 5<sup>th</sup> Round Table Edinburgh June 2015

*Adam Lomax FRCS (Tr & Orth)*

*Barry Rose FRCS (Tr & Orth)*

*Dishan Singh FRCS (Orth)*



*Aspects of Foot and Ankle Surgery*



# Consensus of the 5<sup>th</sup> Round Table

## Edinburgh 2015

*Adam Lomax*

*Barry Rose*

*Dishan Singh*



### Convenors:

Stephen Bendall

Nick Cullen

Sunil Dhar

Nick Geary

Andy Goldberg

Fred Robinson

Dishan Singh

### Hosts:

Ortho Solutions

---

Distilled in this document are the thoughts and opinions with consensus where possible of 30 Orthopaedic Foot and Ankle Consultant Surgeons who gathered from across the United Kingdom, USA and Australia. Though eminence rather than true evidenced based medicine this represents the concepts of over 200 years of combined experience. A basis of invited lectures introduced open and frank discussion from which consensus was sought. The statements herein only represent those of individuals and no claim is made that they are irrefutable. All the percentage figures quoted represent the proportion of the surgeons present who voted on the subject in discussion.

## **Preface**

*The 1<sup>st</sup> Round Table meeting was held in Padua in June 2011, followed by annual meetings in Paris, Barcelona and Budapest. The 5<sup>th</sup> Round Table in Edinburgh has once again not followed the usual orthopaedic meeting format where faculty members lecture to delegates. As always, the meeting is unique in that all participants have an equal input to review the literature and present their individual experience on a topic - with ample time for an informal discussion of the subject in a relaxed setting.*

*Some controversial topics have been chosen so that we can reach a consensus whereas others were chosen so that we can be informed on less common but important conditions. The topics chosen by the convenors included infection in the foot & ankle, hindfoot deformity, ankle arthritis, Achilles tendinopathy and Minimally Invasive Surgery.*

*Adam Lomax and Barry Rose were responsible for recording opinions and capturing the essence of the debates, many of which resulted in consensus being reached on areas of foot and ankle practice. This booklet collates the literature review and the views of all those who participated.*

*This booklet does not represent Level I evidence derived from prospective randomized controlled trials but represents the compilation of the combined experience of 35 British orthopaedic surgeons as well as a much valued input from Markus Knupp from Germany.*

*We have not provided a detailed list of references in order to keep the booklet small and easily readable.*

*I hope that you will find something of use and relevant to your own practice.*

*Dishan Singh, MBChB, FRCS, FRCS (Orth)*

*Consultant Orthopaedic Surgeon*

*Royal National Orthopaedic Hospital*

*Stanmore, United Kingdom*

October 2015

# 5<sup>th</sup> Round Table of Foot and Ankle Surgery

10-12 June 2015 *Edinburgh*

## INFORMATION SESSION: INFECTION IN THE FOOT AND ANKLE

Acute osteomyelitis/ Septic Arthritis	Gillian Jackson
Chronic osteomyelitis	Sunil Dhar
Fungal bone infections	Mark Rogers
Fungal nail infections	James Ritchie

## CONSENSUS SESSION: ADULT ACQUIRED FLAT FOOT

What fails first? The tendon or the hindfoot joints?	Phil Vaughan
Bony correction in stage 2 disease	Tom Ball
Periarticular augmentation	Callum Clark
When and what to fuse in stage 3?	Tim Clough

## CONSENSUS SESSION: SUBTLE PES CAVUS

Aetiology and pathogenesis	Billy Jowett
How I correct the subtle cavo-varus	Raman Dega
Varus with instability and peroneal tendon pathology	Natasha Hossain
Subtle cavus and ankle arthritis	Bob Sharp

## INFORMATION SESSION: MINIMALLY INVASIVE SURGERY

What is MIS?	Carolyn Chadwick
MIS first ray for hallux valgus	George Smith
MIS first ray for hallux rigidus	Mark Herron
MIS in the lesser rays	Paul Hodgson
MIS heel shift	Hari Prem
MIS hindfoot/midfoot excluding heel shift	Matt Morris

#### INFORMATION SESSION: DIFFICULT PROBLEMS IN ANKLE OA

Early management of medial ankle OA	Markus Knupp
Varus end stage ankle OA	Senthil Kumar
Valgus end stage ankle OA	Jason Eyre

#### CONCENSUS SESSION: NON INSERTIONAL ACHILLES TENDONOPATHY

Aetiology	Mike Karski
Diagnosis	Melwyn Pereira
Non operative management	Andy Goldberg
Operative management	Fred Robinson

## Septic Arthritis/Acute Osteomyelitis – Gillian Jackson

### Septic arthritis

Septic arthritis of the ankle accounts for 10-15% of all adult cases. It is most frequently monoarticular. Causes include haematogenous spread, adjacent soft tissue sepsis, penetrating trauma, intra-articular injection, surgery (0.14%- 0.42% incidence following all elective arthroscopy). The highest reported rate of infection post arthroscopy is reported in the ankle (5.7% - Patient Safety in Surgery 2009).

Predisposing factors include rheumatoid arthritis, osteoarthritis, crystal arthropathy, diabetes, chronic illness, immunosuppression, haemodialysis, intravenous drug abuse, skin infection/ ulceration, steroid injection or surgery.

### *Investigations*

Elevation in serum white cell count, CRP and ESR. A joint fluid aspirate with a white cell count > 50,000 has a sensitivity of 100% and a specificity 24%. Peripheral blood cultures should be taken along with a plain radiograph of the joint.

MRI has 100% sensitivity, 75% specificity. Features include: joint effusion, cartilage and bone destruction, soft tissue abscesses, bone oedema and cortical disruption.

Aspiration should always be performed prior to administering antibiotics. Gram stain is positive in only 50% of cases. Cultures are positive in 67% of cases.

### *Treatment*

BSR & BHPR, BOA, RCGP and BSAC guidelines for management of the hot swollen joint in adults (Coakley et al 2006).

No robust evidence on optimal duration of antibiotic treatment, but usually 2 weeks IV followed by 4 weeks oral therapy.

There is no evidence of a difference in outcome from treatment with needle aspiration vs. arthroscopic washout vs. open washout. Goldenberg (1975) compared needle aspiration vs. arthroscopy. There was no significant difference in outcome. Glazebrook et al (2009) found only level IV and V evidence consistently in favour of arthroscopy for septic arthritis. In his review of evidence-based indications for ankle arthroscopy, it had a Grade C recommendation. The studies reviewed reported a 91-98% cure rate.

There is no evidence for the use of IV steroids in conjunction with antibiotics in adults.

Holtom et al (2008) presented a cohort of 30 cases of acute haematogenous septic ankle arthritis. 27% had diabetes and 10% were intravenous drug users. Presenting features were: ankle pain 87%, swelling 70%, fevers 33%, pyrexia on admission 17%. 80% cultured an organism (57% one organism, 23% 2 organisms). 86% grew gram +ve cocci (staph > strep), 17% MRSA, 17% mycobacterium. 30% had concurrent adjacent osteomyelitis (8% in studies of all joints). They conclude that empirical antibiotics should cover gram +ve cocci and one should consider vancomycin.

### *Outcome*

Overall 10 % mortality. Higher in elderly, those with co-morbidities, poly-articular involvement and delayed presentation. There is a 40% risk of permanent loss of joint function.

A systematic review of published case series of arthroscopically treated septic arthritis of the ankle included 15 cases from 9 studies (Mankovecky 2014). All were treated initially arthroscopically, the studies suggested that repeat procedures are required in higher stages of infection. Their own retrospective series of 8 cases were treated successfully with arthroscopic synovectomy, irrigation (10-15 litres) and debridement and IV antibiotics.

### **Acute Osteomyelitis**

Osteomyelitis is inflammation of bone caused by bacteria and rarely fungi or mycobacteria. The continued presence of pathogens plus necrotic bone marks the end of the acute phase and presence of chronic osteomyelitis.

### *Classification*

Waldvogel (1970)

- Haematogenous
- Contiguous
- Associated with vascular insufficiency.

In adults the majority of foot and ankle osteomyelitis is contiguous. Open fractures, surgery, malnutrition, immunosuppression, diabetic ulceration and pressure ulceration are common causes. Haematogenous osteomyelitis is more common in children.

### *Pathogenesis*

Acute osteomyelitis is a suppurative inflammatory process. The inflammatory mediators and leucocytes cause tissue necrosis. The inflammatory process compresses the bones vascular channels and can cause periosteal stripping. The bone vascularity will eventually become obliterated if initial treatment is not instigated or adequate and the inflammatory process persists or worsens. The resulting ischaemia commences the process of bone necrosis with development of sequestra. The condition progresses to chronic osteomyelitis as the antibiotics and inflammatory cells cannot penetrate this avascular area.

The pathogen depends on age and mode of infection. Staphylococcus aureus is the commonest. Coagulase negative staphylococci are often seen in the presence of foreign body and implant related osteomyelitis. Gram-negative infections are seen in the elderly. Polymicrobial infections are seen in diabetics and pressure ulceration including staphylococci, streptococci, gram negative bacilli and anaerobes. Atypical organisms are more common in those with comorbidities and immunocompromise.



### *Investigation*

CRP, ESR- elevated in almost all patients. WCC raised but rarely above 15. Blood cultures and wound swabs should be taken. Consider bone biopsy

#### Plain Radiography

- Up to 2 weeks for 30-50% osteolysis to appear.
- Subtle soft tissue swelling, osteopenia, periosteal thickening.
- Sensitivity 70%. Specificity 50%

#### Ultrasound

- Images and identifies soft tissue abscess and joint effusion. Allows guided biopsy

#### CT Scan

- Sensitive for bone destruction, . Allows guided biopsy.

#### Isotope scan

- Technetium 99 or white cell labelled scan

#### MRI

- Demonstrates early inflammatory change, extent, sequestra and soft tissue and joint involvement.
- Very sensitive: can overestimate acute phase due to bone oedema. Changes can persist for many months.

### *Treatment*

Splintage, analgesia, High dose IV antibiotics to cover common pathogens. Consider vancomycin if history/ risk of MRSA. Fluid resuscitation. Address co-morbidities.

Consider treatment solely with antibiotics if:

- Rapid diagnosis and treatment within days of onset of symptoms
- Imaging confirms no dead bone, intra medullary or soft tissue abscess
- No adjacent septic arthritis
- Rapid response to initial antibiotic therapy
- Tuberculosis

Modify antibiotics after culture and sensitivities obtained.

Surgery should be undertaken if

- No rapid clinical response
- Deterioration
- Progression of disease on imaging
- Dead bone/ abscess or septic arthritis
- Presence of implants.

#### Principles of surgery

- Multiple biopsies for microbiology and histology

- Debridement and drainage of pus
- Decision whether to retain any implant
- Remove implant and temporary stabilization
- Local delivery antibiotics?
- Dead space management
  - Calcium sulphate with antibiotics
  - Calcium sulphate and hydroxyapatite with antibiotics

68-71% union rates found with retention of hardware , debridement and antibiotics in post operative acute osteomyelitis where the construct remained stable. (Mouzopoulos et al 2011)

## References

- Coakley G et al. BSR & BHPR, BOA, RCGP and BSAC guidelines for management of the hot swollen joint in adults Rheumatology 2006;45:1039–1041
- Garcia- Arias M, Balsa A, Mola EM. Septic Arthritis. Best Practice and Research Clinical Rheumatology 2011; 25: 407-421.
- Mouzopoulos G et al Management of bone infections in adults: the surgeon's and microbiologist's perspectives. Injury, Int. J. Care Injured 42 (2011) S5, S18–S23

---

## Chronic Osteomyelitis of the Foot and Ankle – Sunil Dhar

Management must be undertaken as a multi-disciplinary approach. It may be associated with diabetes, or occur in non-diabetics (trauma, surgical site infection). Haematogenous chronic osteomyelitis is rare. Chronic osteomyelitis is still difficult to treat and characterized by frequent relapses. Chronic infections are fundamentally different than acute infections

*Cierny Mader Classification 1985:*

Anatomic Site:	Stage 1 - Medullary
	Stage 2 - Superficial
	Stage 3 - Localised
	Stage 4 – Diffuse
Physiological Class	A Host - Normal
	B Host – Bs –Systemic compromise
	BI – Local compromise
	BIs – Systemic and Local compromise
	C Host – Treatment worse than the disease

### *Biofilm*

Thin layer of **microorganisms** that adheres to the surface of an organic or inorganic structure, together with their secreted polymers. Predominant phenotype of nearly all bacteria in their natural habitat, whether pathogenic or environmental

The biofilm model

- Biofilms form in the presence of necrotic tissue or foreign material (implants)
- Colonized by bacteria
- Surface colonies that multiply and grow in a 3-D fashion
- Polymicrobial, sessile, community-based aggregations embedded in a self-secreted matrix

The biofilm matrix:

- offers bacteria protection from mechanical influences
- prevents antibiotics, host defence cells and antibodies to penetrate, functioning as a diffusion barrier
- after a course of treatment, bacteria can return to an active mode and then show resistance to the originally administered drugs

### *Treatment*

Current management works on the basis that chronic osteomyelitis is primarily a surgical disease.

Principles of surgery are:

- Debride the area of osteomyelitis.
- Take no less than 5 microbiology samples for culture and sensitivity, and 3-5 histology samples
- Excise the area of necrotic bone, aiming for healthy bleeding bone at the cut margins.
- Dead-space management of the cavity, including antibiotic-loaded carriers
- Optional muscle flaps can promote revascularisation and healthy bone formation, and provide soft-tissue coverage of the bone compartment
- Growth of new bone to fill the cavity can be encouraged by bone grafting and osteo-conductive bone graft substitutes.

Multiple antibiotic loaded carriers are available for dead space management, for delivering high doses of antibiotics locally into the cavity: PMMA beads, collagen fleece, calcium sulphate. Recent experiments have combined calcium sulphate with hydroxyapatite (HA) to improve biocompatibility and osteoconductivity. (Stubbs 2004, Raushmann 2005)

### **References**

Raushmann MA, Wichelhaus TA, Stürnal V et al. Nanocrystalline hydroxyapatite and calcium sulphate as biodegradable composite carrier material for local delivery of antibiotics in bone infections. *Biomaterials* 2005;26(15):2677-84.

Stubbs D, Deakin M, Chapman-Sheath et al. In vivo evaluation of resorbable bone graft substitutes in rabbit tibial defect model. *Biomaterials* 2004;25(20):5037-44.

## Fungal Bone Infections of the foot – Mark Rogers

Mycetoma - Chronic, progressive, destructive granulomatous infection of the skin, subcutaneous tissue, fascia, muscle and bone, Mycetoma is endemic in Africa, Mexico and India.

Classical triad:

- Painless subcutaneous mass
- Multiple sinuses
- Sero-purulent discharge

Causal organisms include: species of *Madurella*, *Aspergillus* and *Pseudallescheria*. Causative organism enters tissues of the bare foot or hand after trauma (thorn prick). Infection begins in the skin and subcutaneous tissue, spreading along fascial planes, progressively destroying connective tissue and bone. The involved area is characterised by swelling, multiple sinus formation fistulous tracts and deep abscesses. Progressive enlargement may lead to gross disfigurement of the affected part

Radiographs may show:

- Soft-tissue swelling without bone involvement
- Extrinsic pressure effects on the intact bones in the vicinity of an expanding granuloma
- Periosteal reaction
- Longitudinal spreading along a single ray
- Horizontal spread along a single row
- Multidirectional spread due to uncontrolled infection

The classical “dot-in-circle” sign may also be a feature on MRI and CT scan.

Diagnosis is made on clinical appearance and on surgical tissue biopsy for microscopy and culture. Liaison with microbiologist/infectious disease physician is vital.

The mycology reference laboratory (Mycology RL): <https://www.gov.uk/government/collections/mycology-reference-laboratory-mrl> provides a comprehensive service for the diagnosis and management of fungal infections through its specialist laboratory services and expert clinical and technical advice.

Treatment should be overseen by a microbiologist and depends on aetiological agent, site, extent of disease and how timely the patient presents. Medical management includes a variety of antifungal agents continued for several months. The need for surgery depends on the individual case presentation.

---

## Fungal Nail Infections – James Ritchie

Onychomycosis: A fungal infection of the nails that causes discoloration, thickening and separation from the nail bed. Occurs in 2-8% population with a significant increase with age (20% over 60, 50% over 70).

Associations include: Diabetes, Vasculopathy, Immunocompromise.

Distribution may be:

- Superficial
- Distal subungual
- Proximal subungual

- Total nail dystrophy

One must always consider subungal melanoma and amelanotic melanoma in the differential diagnosis.

Diagnosis is made clinically, or can include direct microscopy, culture and PCR techniques.

### *Treatment*

When required, treatment options include:

- **Topical drugs (eg Amorolfine)**
  - Low risk of drug interactions/adverse effects
  - Efficacy limited by nail plate penetration
  - Superficial disease
  - Maybe more effective in children as thinner, faster-growing nails
- **Systemic drugs (eg Terbinafine, Itraconazole, Fluconazole)**
  - More effective than topical
  - Beware drug interactions
  - Monitor LFTs
  - Efficacy improved by debridement
  - Severe or multiple nail involvement
- **Nail debridement/avulsion**
  - Mechanical with file or dermabrader
  - Chemical: 40% urea under dressing for 2/52 then debridement with clipper
  - Increases efficacy of antifungals
  - Not effective in isolation
- **Laser/phototherapy**
  - Many devices described
  - Some evidence of efficacy
  - No trials comparing laser vs. antifungals

Surgical avulsion:

- Reduces fungal load
- Effective combined with systemic antifungals
- Useful if diagnostic doubt
- May need to splint nail bed
- Avoid in vasculopathies (?Diabetics)

Treatment recommendations:

- If superficial, in few nails: *topical therapy*
- Widespread superficial disease: *systemic or topical therapy*
- Subungal disease: *nail debridement/avulsion plus systemic therapy*:
  - terbinafine if dermatophyte
  - itraconazole if mixed

## Which Fails First to Cause Adult Acquired Flat Foot Deformity? The Tendon or the Hindfoot Joints? - Phil Vaughan

Adult acquired flatfoot is a failure of the osseoligamentous complex (Tryfonidis 2008). Radiographic studies of the joints and ligaments are not conclusive for normal anatomy and alignment to be able to know which fails first.

The 'spring ligament complex' (plantar calcaneonavicular ligament, deltoid ligament, bifurcate ligament, cervical ligaments, plantar fascia, joint capsules) is strongly related to flatfoot deformity (Williams 2014). It can fail in isolation or combination with TPTD. Up to 82% of flat feet due to TPTD have spring ligament tears (Gazdag 1997). It is inconclusive about which fails first. As the severity/grade of TPTD increases, the prevalence of spring ligament pathology increases in a dose response fashion (Shibuya 2008). In TPTD the tendon seems therefore to fail before the osseoligamentous complex. Once the tendon starts to fail, deformity occurs due to spring ligament dysfunction.

For isolated spring ligament rupture there are only case reports/series (Orr 2013, Tryfonidis 2008, Borton 1997). Generally, there are two groups:

- acute deterioration, young, active, clear history of trauma
- chronic deterioration, older, less active, vague history of trauma, more likely to have co-morbidities

There is no evidence regarding failure of the subtalar interosseous ligament as a cause for the pathology seen. In the adult acquired flatfoot deformity without TPTD, the hindfoot fails first, before the tendon. Once the spring ligament is injured, deformity occurs due to spring ligament dysfunction

Summary:

- Acute flat foot - joint fails first
- Chronic flat foot - tendon fails first

References:

Gazdag AR, Cracchiolo A. Rupture of the posterior tibial tendon. Evaluation of injury of the spring ligament and clinical assessment of tendon transfer and ligament repair. *J Bone Joint Surg A* 1997;79:675–81.

Orr JD, Nunley JA 2nd. Isolated spring ligament failure as a cause of adult-acquired flatfoot deformity. *Foot Ankle Int.* 2013 Jun;34(6):818–23.

Tryfonidis M, Jackson W, Mansour R, Cooke PH, Teh J, Ostlere S, Sharp RJ. Acquired adult flat foot due to isolated plantar calcaneonavicular (spring) ligament insufficiency with a normal tibialis posterior tendon. *Foot Ankle Surg.* 2008;14(2):89–95.

Williams G, Widnall J, Evans P, Platt S. Could failure of the spring ligament complex be the driving force behind the development of the adult flatfoot deformity? *J Foot Ankle Surg.* 2014 Mar-Apr;53(2):152–5.

---

## Bony Correction in Stage 2 Tibialis Posterior Tendon Dysfunction – Tom Ball

Stage 2 flatfoot is usually a result of TPTD (Johnson 1989). The aims of treatment may include: to reverse the pathology, normalise forces across the hindfoot, restore the medial arch, pain relief, function restoration, to prevent progression to stage 3.

Orthotics should be tried first. If this approach fails, surgery may be undertaken:

Repair/reinforce the tibialis posterior tendon

- Options include: direct repair or advancement; FDL transfer; FHL transfer; or split tibialis anterior transfer (Cobb)
- Knupp (2007) - 22 patients had a Cobb procedure. Good AOFAS improvement was seen with no tibialis anterior weakness, although most had another procedure (e.g. calcaneal osteotomy, deltoid repair)

Normalise the forces across the hindfoot

- Calcaneal osteotomy (MDCO) to medialise the ground reaction force and make the achilles an inverter.
- Guyton (2001) - 26 patients had MDCO and FDL transfer. At 32 months, 50% noted a change in foot shape. Pain relief was good in 75% and excellent in 16%.
- Myerson (2004) - 129 patients had MDCO and FDL transfer. 118 were highly satisfied, 97% experienced pain relief; mean post-operative AOFAS score 79; 84% able to wear shoes without orthotics post-operatively.

Parsons (2010) sub-categorised stage 2 into 2a (forefoot varus <15 degrees), 2b (forefoot varus >15 degrees), 2c (forefoot varus fixed). Bluman (2007) also subclassified stage 2.

Lateral column lengthening corrects the uncovered talar head (>40% uncovering is the indication – Myerson), reduces subtalar subluxation, corrects forefoot abduction and may plantarflex first ray indirectly by the windlass effect. Marks (2009) prospectively compared lateral column lengthening and MDCO/FDL transfer. Both showed improved gait and hindfoot and forefoot parameters. Better heel inversion was seen with lateral column lengthening. Bolt (2007) suggested that lateral column lengthening gave a better correction and lower re-operation rate, but higher non-union rate and possible adjacent (CCI) OA.

#### Conclusion

- Models of flat foot are becoming more nuanced.
- Increasingly inventive operations are becoming popular.
- An “a la carte” approach is now possible.
- Evidence lags behind the pace of innovation.

#### References:

Guyton GF, Jeng C, Krieger LE, Mann RA. Flexor digitorum longus transfer and medial displacement calcaneal osteotomy for posterior tibial tendon dysfunction: a middle-term clinical follow-up. *Foot Ankle Int* 2001;22(3):627-632.

Marks RM, Long JT, Ness ME, Khazzam M, Harris GF. Surgical reconstruction of posterior tibial tendon dysfunction: prospective comparison of flexor digitorum longus substitution combined with lateral column lengthening or medial displacement calcaneal osteotomy. *Gait Posture*. 2009 Jan;29(1):17-22.

Parsons S, Naim S, Richards PJ, McBride D. Correction and prevention of deformity in type 2 tibialis posterior dysfunction. *Clin Orthop Relat Res*. 2010 Apr;468(4):1025-32.

Tankson CJ. The Cotton osteotomy: indications and techniques. *Foot Ankle Clin*. 2007;12(2):309–315.

---

## Adult Acquired Flatfoot: Peri-articular Augmentation – Callum Clark

The spring (plantar calcaneo-navicular) ligament fails - it is this fundamentally that could be augmented. It can be repaired or reconstructed.

#### Repair:

- pants over vest
- intraosseous suture through the navicular, but not if mid-substance tear
- suture anchor into navicular or sustentaculum if not mid-substance
- can augment repair with tibialis posterior stump, or loop back the FDL

#### Reconstruction with autograft:

- a number of techniques are described, including free hamstrings, peroneus longus

- Thordarson (1995) assessed four cadaveric techniques (peroneus longus, two split tibialis anterior methods, achilles allograft), finding the peroneus longus to be best under loading
- Choi (2003) assessed differing peroneus longus tunnel positions, concluding that a supero-medial/plantar passage of the tendon through calcaneum/navicular was best
- Tan (2010) assessed a tibialis anterior allograft, which as a sling under the talar head
- Baxter (2015) assessed three methods of free peroneus longus allograft, finding the talo-navicular reconstruction to be best
- In the only clinical series (Williams 2010) 13 patients all underwent lateral column lengthening, FDL transfer and spring ligament repair, most with a medialising calcaneal osteotomy. Peroneus longus was harvested proximally and left attached to the medial cuneiform. 10 were routed to the calcaneum, four to the tibia. Good restoration of angles was seen but there were many confounding variables
- The Internal Brace (Acevedo 2013) is a new option, but there is no clinical evidence of outcomes.

The arthroereisis screw may be considered. Viladot (2003) presented 21 patients with good results. Needleman (2006) presented 28 patients. 39% had the screw removed for pain, but with post-operative angles maintained. The screw may be used to protect the medial repair in standard stage 2 cases, and in isolated spring ligament and deltoid rupture. It was suggested that the device is removed at six months post-operatively due to observed symptoms from the device.

The presenter reported his series of 22 feet. In all cases, patients had a standard FDL transfer, spring ligament repair augmented with tibialis posterior stump, MDCO and an arthroereisis screw. All arthroereisis screws were removed electively at six months. With a mean follow-up of three years, the mean post-op MOXFQ was 15.2 and EQ5D was 6.9. No collapse seen after removal of the screw.

#### References:

Acevedo J, Vora A. Anatomical reconstruction of the spring ligament complex: "internal brace" augmentation. *Foot Ankle Spec.* 2013 Dec;6(6):441-5.  
 Baxter JR, LaMothe JM, Walls RJ, Prado MP, Gilbert SL, Deland JT. Reconstruction of the medial talonavicular joint in simulated flatfoot deformity. *Foot Ankle Int.* 2015 Apr;36(4):424-9.  
 Needleman RL. A surgical approach for flexible flatfeet in adults including a subtalar arthroereisis with the MBA sinus tarsi implant. *Foot Ankle Int.* 2006 Jan;27(1):9-18.  
 Williams BR, Ellis SJ, Deyer TW, Pavlov H, Deland JT. Reconstruction of the spring ligament using a peroneus longus autograft tendon transfer. *Foot Ankle Int.* 2010 Jul;31(7):567-77.

---

## Adult Acquired Flatfoot: When and What to Fuse in Stage 3? – Tim Clough

The traditional approach has been a dual incision triple fusion, with potential complications of wound healing, non-union, mal-union and late midfoot osteoarthritis.

Saltzman (1999) reported 67 triple arthrodesis with 25 and 44 year follow-up. 78 percent had some residual deformity but these were non-progressive. Pseudarthrosis occurred in thirteen feet. All of the ankles had some degenerative changes. Similar progressive arthritic findings were noted at the naviculocuneiform and tarsometatarsal joints. Despite progressive symptoms and radiographic degeneration in the joints of the ankle and midfoot, 54 patients (95 percent) were satisfied with the result of the operation.

Graves (1993) reported, at a mean follow-up of four years, 18% nonunion rate, 65% with some discomfort, and 41% with progressive ankle or midfoot osteoarthritis. Overall, fourteen of the seventeen patients were satisfied with the result of the operation. Smith (2004) reported 23-27% ankles, naviculocuneiform or tarsometatarsal joints osteoarthritis at 14 year follow-up. 59% had pain on moderate activity, and 74% reported moderate-to-severe difficulty with, or an inability to negotiate, uneven surfaces. There were no non-unions.



The single incision medial approach was reported by Jeng (2005) in 17 patients, with a 12% calcaneocuboid joint asymptomatic non-union rate. Jackson (2007) also presented successful results, with no wound problems.

Subsequently the technique was modified to a medial approach double arthrodesis (subtalar and talonavicular joints). Sammarco (2006) reported good AOFAS score improvement, and Knupp (2009) reported good results. No late lateral midfoot pain (from the calcaneocuboid joint) was seen. This raises question of not needing to fuse the calcaneocuboid joint if the non-union rate might be approximately 10%, and good results can be achieved with a double arthrodesis.

Arthroscopic triple and modified double fusions have been recently reported by Parsons (2015). All of the triple fusions united, and there was a 21% non-union rate for the talonavicular joint (2/3 symptomatic) in a modified double arthrodesis.

#### Summary:

- The traditional triple fusion is not benign.
- The presenter performs a modified double, though an open medial approach, with no wound problems.
- Could consider arthroscopic surgery

#### References:

Graves SC, Mann RA, Graves KO. Triple arthrodesis in older adults. Results after long-term follow-up. J Bone Joint Surg Am. 1993 Mar;75(3):355-62.  
Jackson WFM, Tryfonidis M, Cooke PH, Sharp RJ. Arthrodesis of the hindfoot for valgus deformity: an entirely medial approach. J Bone Joint Surg [Br] 2007;89-B:925-7.  
Jagodzinski NA, Parsons AM, Parsons SW. Arthroscopic triple and modified double hindfoot arthrodesis. Foot Ankle Surg. 2015 Jun;21(2):97-102.  
Knupp M, Schuh R, Stufkens SA, Bolliger L, Hintermann B. Subtalar and talonavicular arthrodesis through a single medial approach for the correction of severe planovalgus deformity. BJ 2009 May;91(5):612-5.  
Saltzman CL, Fehrle MJ, Cooper RR, Spencer EC, Ponseti IV. Triple arthrodesis: twenty-five and forty-four-year average follow-up of the same patients. J Bone Joint Surg Am. 1999 Oct;81(10):1391-402.  
Smith RW, Shen W, Dewitt S, Reischl SF. Triple arthrodesis in adults with non-paralytic disease. A minimum ten-year follow-up study. J Bone Joint Surg Am. 2004 Dec;86-A(12):2707-13.

---

## Consensus

Who has seen an acute flatfoot, with a functioning tibialis posterior?

Yes	28
No	3

Who has seen a chronic flatfoot, with functioning tibialis posterior?

Yes	9
No	22

How many believe that the larger group of people have a pre-existing flatfoot?

Yes	17
No	9
Unsure	5

**How would you address a Stage 2a: flatfoot deformity, fully passively correctable, forefoot varus <15 degrees**

Which tendon transfer?

FDL	30
Cobb	1

Do you tenodesis the tibialis posterior proximally onto FDL?

Yes 13  
No 18

What do you do with the tibialis posterior tendon?

Excise 22  
Preserve 5  
Unsure 4

Who performs a medialising displacement calcaneal osteotomy (MDCO) ?

Yes 31  
No 0

Who performs the MDCO minimally invasively?

Yes 8  
No 23

Who routinely addresses the spring ligament?

Yes 19  
No 12

How do you repair the spring ligament?

Routinely direct repair with no augmentation 20  
Routinely repairs with augmentation 5

Who has used the internal brace?

Yes 6  
No 25

Who routinely performs a Cotton osteotomy for stage 2a?

Yes 1  
No 30

**How would you address a Stage 2b: flatfoot deformity, fully passively correctable, forefoot varus >15**

Who uses an arthroereisis screw?

Yes 4 (some in selected cases)  
No 27

Who performs a lateral column lengthening?

Yes 1  
No 30

Who believes the post-operative foot shape relates to the success of the procedure?

Yes 9  
No 22

**How would you address a Stage 2c: flatfoot deformity not fully passively correctable**

Who believes a tendon transfer, MDCO, Cotton osteotomy and spring ligament repair will reliably correct the deformity in stage 2c:

Yes 8  
No 23

## Aetiology and Pathogenesis of subtle pes cavus– Billy Jowett

The phrase “subtle pes cavus” was coined by Manoli and Graham in 2005, Manoli had also previously described the “peek-a-boo” heel sign, seen in the varus hindfoot . This is usually an anterior cavus, with plantar flexion of the 1<sup>st</sup> metatarsal resulting in a forefoot driven hindfoot varus. Clawing of the toes is usually absent. (Manoli and Graham 2005, Abbasian and Pomeroy 2013).

On plain radiography, the following features can be seen:

Lateral standing foot x-ray:

- break in Meary’s line
- increased distance between the inferior surface of the medial cuneiform and the base of the 5<sup>th</sup> metatarsal
- posterior position of the fibula
- dorsiflexion of the os calcis

AP standing foot x-ray

- reduction of talocalcaneal angle
- metatarsal overlap
- (metatarsus adductus)

The incidence of subtle pes cavus is unknown as the diagnosis is subjective and associated with a large inter observer variation. Many cases are idiopathic. There may be a familial component but the genetic components are poorly delineated. The condition may represent a normal variant, but one that is associated with a large number of pathological conditions.

In the development and progression of the deformity, the plantar flexed 1<sup>st</sup> metatarsal results in the medial aspect of the forefoot striking the ground early during the gait cycle. This is initially flexible, but progressed through to a fixed deformity. Due to the tripod effect, the heel is subsequently driven into a varus position, which again progresses from a flexible to a fixed deformity. In heel varus, the gastrocnemius become tight, further medialising the heel and progressing the deformity.

The permanently supinated position of the forefoot and varus position of the hindfoot prevents unlocking of the Chopart joints during the stance phase of gait. The shock absorbing capacity of the foot is therefore lost. The result is:

- forefoot overload
- lateral column overload
- hindfoot instability
- Achilles/plantar fascia pathology

## References

Abbasian A<sup>1</sup> & Pomeroy G. The idiopathic cavus foot-not so subtle after all. Foot Ankle Clin. 2013;18(4):629-42.

Manoli A 2<sup>nd</sup> & Graham B. The subtle cavus foot, "the underpronator". Foot Ankle Int. 2005;26(3):256-63.

Manoli A 2<sup>nd</sup>, Smith DG, Hansen ST Jr. Scarred muscle excision for the treatment of established ischemic contracture of the lower extremity. Clin Orthop Relat Res. 1993;(292):309-14.

## How I Correct the subtle cavo-varus foot – Raman Dega

### Conservative management

- Orthotics (Burns 2010)
  - 1<sup>st</sup> metatarsal recess
  - Slight heel raise
  - Lateral forefoot wedge
- Physiotherapy

### Operative management – a combination of:

- 1<sup>st</sup> Metatarsal lifting osteotomy
- Medial column osteotomy
- Peroneus longus to brevis tenodesis
- Lateral ligament reconstruction
- Calcaneal osteotomy
- Jones procedure to big toe
- Tendo Achilles lengthening/ gastrocnemius recession

Combination operations are bespoke to each patient and the presenting features seen in each individual case.

Maskill (2010) published data on 35 patients with subtle cavovarus (without neurological cause) treated surgically with combination operations, all had lateral sided pain. A systematic approach was taken to clinical examination, with documentation of Silverskiold test, peek a boo heel sign, Coleman block test, tendon function and radiographic findings. Procedures carried out were

• Calcaneal osteotomy	100%
• Peroneus Longus to Peroneus Brevis transfer	86%
• Dorsiflexion 1 <sup>st</sup> MT	86%
• Percutaneous tendo Achilles lengthening	28%
• Gastrocnemius recession	17%
• Ankle ligament reconstruction	17%

At 4.4 yrs follow up, AOFAS increased from pre op 45 to post op 90.

The osteotomy may be performed open, although increasingly an MIS approach is being used – providing the benefit of a small incision and avoiding the need for parallel incisions when peroneal tendon surgery is also required.

Overall, subtle pes cavovarus must be looked for in a wide variety of pathologies. Lateralising calcaneal osteotomy is a good operation, and further combination procedures can then be built around this after accurate assessment of each individual case.

### References:

Burns J, Landorf KB, Ryan MM, Crosbie J, Ouvrier RA. Interventions for the prevention and treatment of pes cavus. The Cochrane Collaboration. 2010.

Maskill MP, Maskill JD, Pomeroy GC. Surgical management and treatment algorithm for the subtle cavovarus foot. Foot Ankle Int. 2010;31(12):1057-63.

## Subtle Pes Cavus with Ankle Instability – Natasha Hossain

Subtle pes cavus results in recurrent inversion sprains of the ankle and occasionally the subtalar joint, and walking on the outer border of the foot leads to:

- Base of 5<sup>th</sup> MT fractures
- Stress fractures of lesser MTs
- Peroneal tendon pathologies & subluxations
- Os peroneum syndrome
- Enlarged painful peroneal tubercle

After subtle pes cavus has been identified, define the patient's specific complaint. Treatment has to be a combination of correction of the deformity and addressing the specific symptoms. Treatment options for the subtle pes cavus:

- **Non-surgical**
  - Targeted physiotherapy
  - Orthotics
  - Selecting appropriate footwear
- **Surgical** – treatment is individualised and may include
  - Proximal medial gastrocnemius release
  - Lateralising calcaneal osteotomy
  - Lateral ligament reconstruction
  - 1<sup>st</sup> ray dorsiflexion osteotomy
  - Peroneus Longus to Peroneus Brevis tendon transfer
  - Peroneal tendon exploration and repair

Larsen and Angermann (1990) found increased frequency of cavovarus foot in patients who had lateral instability. All patients had failed lateral ligament reconstruction due to mechanical malalignment. Similar results were found by Colville (1998).

Treatment of ankle instability:

- EUA ankle and ankle arthroscopic assessment
- Brostrum Gould
- Chrisman Snook if ligament poor or absent
- If poor peroneus brevis then use internal brace to reinforce

Conclusion:

- Have to have a high index of suspicion in patients that present with recurrent instability, failed previous lateral ligament surgery or lateral foot pain
- Surgical intervention only should be considered after failed non surgical treatment
- Surgery needs to be individualised

## References

- Colville MR. Surgical treatment of the unstable ankle. J Am Acad Orthop Surg. 1998;6(6):368-77.
- Larsen E, Angermann P. Association of ankle instability and foot deformity. Acta Orthop Scand. 1990;136-9.

## Subtle Pes Cavus and Ankle arthritis – Bob Sharp

The natural history of the mal-aligned foot and ankle and the development of OA remain unknown. Evidence for the surgical management of subtle cavus foot and ankle OA:

*Mild-moderate OA and subtle cavus foot – Fortin (2002)*

- 13 patients with mild/moderate OA ankle and varus hindfoot
- Lateral ligament reconstruction + calcaneal osteotomy +/- dorsiflexion 1<sup>st</sup> metatarsal osteotomy
- All patients had resolution of pain and instability

*Ankle OA and realignment of varus hindfoot – Lee (2009)*

- 11 patients with stage 2 or 3 OA ankle –mean follow up 22.3 months
- underwent joint debridement, cheilectomy, lateralising calcaneal osteotomy, deltoid ligament release, lateral ligament reconstruction
- Mean talar tilt angle improved from 7.4 to 5.9 degrees
- Mean AOFAS improved from 42.8 to 82.7

Valderrabano (2009) noted in a study of 406 ankles, that the majority were in varus malalignment regardless of aetiology. It remains unclear whether the varus is the cause or the effect of ankle OA.

Does varus malalignment matter?

- Sub talar joint can accommodate for malalignment

But –

- Valgus is accommodated better than varus
- Possible that in the cavus foot the fixed hindfoot varus prevents the subtalar joint from accommodating for the deformity

Does the magnitude of the deformity matter?

- Lee (2011) showed that there was no correlation between the measured angle and the degree of OA

When assessing the deformity, it is important to consider the deformity in 3 dimensional terms, and assess the whole limb on weight bearing alignment views. Gait analysis is also important in these cases. Correction of the deformity may be necessary above the ankle, at the joint level, or below the ankle joint level.

Is supramalleolar osteotomy the answer to varus ankle deformity?

- No longitudinal comparative studies of outcomes of SMO vs. nothing
- Many small short term series show benefits vs. preoperative state (Colin 2014, Giannini 2007, Irwin 2010, Kim 2014, Knupp 2011, Krause 2012, Lee 2009, Stamtis 2003)
- Early OA benefits more than late OA
- One study showed failure if >7.3 degrees of initial varus deformity (Lee 2009)
- Some show correlation of outcome to correction but not all
- Some studies show it is cartilage repair more important than angular correction
- Failure in late OA or leaving axis medial for varus corrections
- Valgus might do better than varus

## References

- Fortin PT, Guettler J, Manoli A 2nd. Idiopathic cavovarus and lateral ankle instability: recognition and treatment implications relating to ankle arthritis. *Foot Ankle Int.* 2002 Nov;23(11):1031-7.
- Krause FG, Henning J, Pfander G, Weber M. Cavovarus foot realignment to treat anteromedial ankle arthrosis. *Foot Ankle Int.* 2013;34(1):54-64.
- Lee W-C, Moon J-S, Lee K, Byun WJ, Lee SH. Indications for Supramalleolar Osteotomy in Patients with Ankle Osteoarthritis and Varus Deformity. *J Bone Joint Surg Am*, 2011;93(13):1243 -1248.
- Valderrabano V, Horisberger M, Russell I, Dougall H, Hintermann B. Etiology of ankle osteoarthritis. *Clin Orthop Relat Res.* 2009;467(7):1800-6.

## Consensus:

In a 35-year-old male with bilateral subtle pes cavus (no lesser toe deformities), would you send the patient for a neurological opinion?

Yes: 12  
No: 19

Have you seen a positive diagnosis of a neurological condition in a patient with subtle cavovarus feet?

Yes: 3  
No: 28

In the same patient – would you send for a neurological opinion if this was unilateral or if there was a family history of cavovarus feet?

Yes: 31  
No: 0

Do you think that all cavovarus feet are neurological?

Yes: 23  
No: 8

Do you believe that subtle cavovarus feet are abnormal?

Yes: 30  
No: 1

In a patient with recurrent ankle instability and subtle cavovarus feet, do you correct the subtle cavus as part of the reconstructive surgery?

Yes: 30  
No: 1

In the correction of the subtle cavovarus foot, do you perform?

- 1) Lateralising calcaneal osteotomy?  
Always: 26  
Selective cases: 5  
Never: 0
- 2) Dorsiflexion 1<sup>st</sup> metatarsal osteotomy?  
Always: 12  
Selective cases: 19  
Never: 0
- 3) Peroneus longus to brevis transfer?  
Always: 9  
Selective cases: 10  
Never: 12

## What is Minimally Invasive Surgery (MIS) of the foot and ankle? – Carolyn Chadwick

The definition is unclear. There are potential advantages to a minimally invasive surgical technique: minimise adjacent soft tissue injury, ?lower morbidity, ?quicker healing, ?quicker return to function. Disadvantages include: need for specific equipment, specific post-operative regime, steep learning curve, dedicated course requirement.

The historical development of MIS was outlined. The Reverdin-Isham, Magnan (2005), and modified Bosch/Giannini osteotomies (Kadakia 2007) were discussed, the latter being abandoned following an unacceptably high complications rate, although Iannò (2013) presented good results. Giannini (2013) described good results with the SERI procedure, as did Di Giorgio (2013) using the Endolog system..

### Conclusion:

- MIS is not one simple instrument or operation
- It is a selection of techniques using small skin incisions and minimal soft tissue disruption, without compromise to the resulting correction.
- It must allow reliable and reproducible results
- The outcomes must be equal to or better than open
- MIS is growing in the UK with good anecdotal outcomes, but little robust data

### References:

Bauer T. Percutaneous forefoot surgery. *Orthop Traumatol Surg Res.* 2014 Feb;100(1 Suppl):S191-204.  
Iannò B, Familiari F, De Gori M, Galasso O, Ranuccio F, Gasparini G. Midterm results and complications after minimally invasive distal metatarsal osteotomy for treatment of hallux valgus. *Foot Ankle Int.* 2013 Jul;34(7):969-77.  
Kadakia AR, Smerek JP, Myerson MS. Radiographic results after percutaneous distal metatarsal osteotomy for correction of hallux valgus deformity. *Foot Ankle Int.* 2007 Mar;28(3):355-60.  
Magnan B, Pezzè L, Rossi N, Bartolozzi P. Percutaneous distal metatarsal osteotomy for correction of hallux valgus. *J Bone Joint Surg Am.* 2005 Jun;87(6):1191-9.  
Radwan YA, Mansour AM. Percutaneous distal metatarsal osteotomy versus distal chevron osteotomy for correction of mild-to-moderate hallux valgus deformity. *Arch Orthop Trauma Surg.* 2012 Nov;132(11):1539-46

---

## Minimally Invasive Surgery for Hallux Valgus – George Smith

Multiple procedures have been described, and not all outcomes are successful. MIS surgery for hallux valgus has large variability in exposure (percutaneous/arthroscopic/mini open/small incision), extra- or intra-articular, bunion resection, lateral release, osteotomy method, osteotomy style, and fixation methods.

Current UK MIS practice was discussed, including the SERI, Bosch and MICA techniques. The current opinion was discussed at BOFAS (Perera, Lomax, Singh). Evidence from the following authors was discussed, presenting good outcomes: Weinberger, Portaluri, Sanna, Bösch, Giannini, Lin, Magnan, Maffulli and Brogan. Evidence of poorer outcomes was published by: Huang, Iannò, Dhukaram and Kadakia.

Systematic reviews by Maffulli (2011) and Trnka (2013) suggest that MIS as a concept 'seems to work'. It has an acceptable complication profile, but more good quality research is needed. There is significant publication bias, and studies come from technique-originator data. If the results are good, why is MIS not common practice? Possibly as failures are not being published.

NICE guidelines suggest the current evidence is limited and inconsistent, relating to a range of different surgical techniques. The evidence on safety is inadequate.



In summary:

- The best evidence is from three comparative studies showing two equivalent outcomes and one poor outcome.
- There are >2000 osteotomies in case series with generally good results.
- Where are the failures – are they not being published?

References:

Bösch P, Wanke S, Legenstein R. Hallux valgus correction by the method of Bösch: a new technique with a seven-to-ten-year follow-up. *Foot Ankle Clin.* 2000 Sep;5(3):485-98.

Curran S, Marudanayagam A, Beddard L, Perera A. A case-controlled study of minimally invasive vs open hallux valgus surgery. *J Foot Ankle Res.* 2015;8(Suppl 1): A14.

Dhukaram V, Chapman AP, Upadhyay PK. Minimally invasive forefoot surgery: a cadaveric study. *Foot Ankle Int.* 2012 Dec;33(12):1139-44.

Giannini S, Cavallo M, Faldini C, Luciani D, Vannini F. The SERI distal metatarsal osteotomy and Scarf osteotomy provide similar correction of hallux valgus. *Clin Orthop Relat Res.* 2013 Jul;471(7):2305-11.

Huang PJ, Lin YC, Fu YC, Yang YH, Cheng YM. Radiographic evaluation of minimally invasive distal metatarsal osteotomy for hallux valgus. *Foot Ankle Int.* 2011 May;32(5):S503-7.

Iannò B et al. Midterm results and complications after minimally invasive distal metatarsal osteotomy for treatment of hallux valgus. *Foot Ankle Int.* 2013 Jul;34(7):969-77.

Maffulli N, Longo UG, Marinozzi A, Denaro V. Hallux valgus: effectiveness and safety of minimally invasive surgery. A systematic review. *Br Med Bull.* 2011;97:149-67.

Magnan B, Pezzè L, Rossi N, Bartolozzi P. Percutaneous distal metatarsal osteotomy for correction of hallux valgus. *J Bone Joint Surg Am.* 2005 Jun;87(6):1191-9.

Perera A, Singh D, Lomax A. Minimally invasive forefoot surgery. *J Trauma & Orthopaedics.* 2015;3(1):50-54.

Trnka HJ, Krenn S, Schuh R. Minimally invasive hallux valgus surgery: a critical review of the evidence. *Int Orthop.* 2013 Sep;37(9):1731-5.

---

## Minimally Invasive Surgery for Hallux Rigidus – Mark Herron

Treatment objectives are predominantly pain relief. Increase in range is only occasionally relevant. The results of open surgery are good: for cheilectomy and debridement, 80-90% are satisfied. for fusion union rate is 95% with 80% satisfaction.

The current practice of joint sparing surgery was discussed, including MIS cheilectomy, MTPJ arthroscopy, Moberg procedure and sesamoidectomy. The indications may include: grade 1 and 2 osteoarthritis; patients who absolutely refuse a fusion and accept the statistics of failure; pure impingement with a well preserved joint, chondral/osteochondral cases (often younger, higher athletic levels).

The techniques and after-care of MIS cheilectomy and arthroscopy were discussed. The literature has small series and anecdotal reviews with no trials or comparisons: Frey (1999, 2009), Davis (1999), Debnath (2006), Van Dijk (1998), Siclari A (2015). There is limited role for arthroscopic first MTPJ fusion, although evidence by Bauer (2010) and Fanous (2014) shows good results.

From the presenter's personal experience early active mobilisation is predictably easier (1 week ); there are fewer/shorter lived scar vs shoe-wear issues and immediate post-operative pain is often minimal.

Summary

There is a role for MIS surgery for hallux rigidus, however it is still an invasive procedure

References:

Bauer T, Lortat-Jacob A, Hardy P. First metatarsophalangeal joint percutaneous arthrodesis. *Orthop Traumatol Surg Res.* 2010 Sep;96(5)

Fanous RN, Ridgers S, Sott AH. Minimally invasive arthrodesis of the first metatarsophalangeal joint for hallux rigidus. *Foot Ankle Surg.* 2014 Sep;20(3):170-3.  
van Dijk CN, Veenstra KM, Nuesch BC. Arthroscopic surgery of the metatarsophalangeal first joint. *Arthroscopy.* 1998 Nov-Dec;14(8):851-5.

---

## Minimally Invasive Surgery in the lesser toes – Paul Hodgson

Procedures include: Distal minimally invasive metatarsal osteotomies (DMMO), Tailor's bunion/ bunionette, lesser toe deformities.

### DMMO

- Alternative to Weil's osteotomy
- Extracapsular, so may cause less stiffness than Weil's osteotomy
- Dynamic correction - no fixation

Complications include delayed union (5%), Non union (1%), Mal-union (increased with simultaneous hallux valgus surgery), soft tissue problems, incorrect osteotomy plane (Bauer, Kakwani, Redfern). One comparative study compares Weil's osteotomy and DMMO in 72 patients. AOFAS scores and recurrence rates were similar. All achieved union, with no increases range of movement in the DMMO group. There was a longer recovery time in the DMMO group, with swelling/oedema and post-operative pain (Henry 2011).

Bunionette surgery may be sub-classified. Treatment for a straight 5th metatarsal is by lateral eminence resection, whereas for a varus 5th toe surgery may involve a DMMO or proximal closing wedge osteotomy. If there is rotation of the 5th toe, a proximal phalanx osteotomy can be performed. There are no comparative studies, although complications are said to be rare (Redfern 2015).

For lesser toe deformities there are no comparative studies. Soft-tissue procedures include flexor tenotomies, extensor tenotomies and joint releases (MTPJ and PIPJ). Bone procedures may be extra-articular (phalangeal osteotomy), or intra-articular (condylectomy, condyloplasty, fusion) Redfern (2015) states that "infection is rare", and the "risk of neurovascular injury is low if the techniques are carried out carefully". Piclet-Legre (2009) presents good results.

### Summary

- Lesser ray MIS surgery uses dynamic correction i.e. no fixation
- Lack of comparative studies
- Swelling and union may take longer

### References:

Bauer T. Percutaneous surgery for static metatarsalgia. In: Maffulli N, Easley M, eds. *Minimally invasive surgery of the foot and ankle.* London: Springer; 2011:157–162.  
Henry J, Besse JL, Fessy MH. Distal osteotomy of the lateral metatarsals: a series of 72 cases comparing the Weil osteotomy and the DMMO percutaneous osteotomy. *Orthop Traumatol Surg Res* 2011;97:557-65.  
Redfern D, Vernois, J, Legré BP. Percutaneous surgery of the forefoot. *Clin Podiatr Med Surg.* 2015;32:291-332

---

## Minimally Invasive Heel Shift – Hari Prem

The indications were discussed, which include: avoiding skin tension, especially when tram line lateral incisions may be performed; acquired flat foot reconstruction; cavus foot reconstruction; calcaneus deformity.

In a cadaveric study of 13 specimens by Mason (2014), there was no nerve injury in 11 patients, but in two cases, a "very small" lateral calcaneal branch was transected. 1 to 5 calcaneal branches were seen. The minimum distance from the burr to the sural nerve was 9mm, and from the entry point to a calcaneal branch was <6mm. No medial damage was seen, including medial calcaneal branches. The safe for MIS is 1cm further away from the lateral malleolus.

The steps of the technique were discussed, including: careful periosteal elevation, cutting the near cortex first then the far side, levering the fragment prior to fixation. A straight cut may be made. A chevron osteotomy may be more stable, but could be more difficult to shift. There is bone loss by use of the burr.

The following may be advantages of MIS heel shift:

- Smaller foot print – no wound dehiscence
- Faster – with practice
- Mobile fragment due to 3mm gap – easy shift
- No greater damage to small calcaneal branches than open

Disadvantages include:

- More bone removal with the burr than with a saw
- Burr costs more than saw blade
- Learning curve

References:

Mason LW, Durston A, Okwerekwu G, Kadambande S, Hariharan K. Minimally invasive calcaneal osteotomies: are neurovascular structures at risk? A cadaveric study. *Bone Joint J* 2014;96-B:SUPP 17 24

Lawrence SJ, Botte MJ. The sural nerve in the foot and ankle: an anatomic study with clinical and surgical implications. *Foot Ankle Int* 1994;15:490-94

---

## Minimally Invasive hindfoot/midfoot excluding heel shift – Matt Morris

These include: calcaneal osteotomies, cheilectomy/bumpectomy, and arthroscopy. The Zadek osteotomy is well-established, and safe. MIS offers no compromise in the technique. Evidence suggests there is 12-15% incidence of wound problems (Taylor 2014, Kumar 2010).

The presenter described his last 10 open compared to first 10 MIS Zadek osteotomies. Good results have been seen, with no difference in healing. One screw was removed in each group, and one temporary sural neuropraxia was seen in the MIS group. More than 30 have now been performed with good outcomes and no healing problems, but not yet published.

The Dwyer lateral closing wedge osteotomy was discussed and compared with lateral shift for cavovarus feet. MIS enables both techniques to be combined, with a smaller wedge excision and smaller lateral shift to achieve correction.

The burr may be used to remove bony prominences, especially in high risk patients. The technique is especially useful in high risk patients. Patient selection is important. Potential prominences include: first TMTJ osteophytes, navicular/talar head, rocker bottom foot, first metatarsal head, base of fifth metatarsal. The soft tissue attachments to these prominences must be respected.

---

## Early Management of Medial Ankle osteoarthritis – Marcus Knupp

Staged treatment of ankle OA:

- Joint preserving
  - Arthroscopy and debridement
  - Arthrotomy and debridement
  - Distraction
  - Osteochondral Ankle Joint Resurfacing
  - Corrective osteotomies
- Joint sacrificing
  - Arthroplasty
  - Arthrodesis

Why consider osteotomy?

- Malalignment is present in 60% of cases of ankle OA
- Fusion and TAR not always a definitive solution in young patients

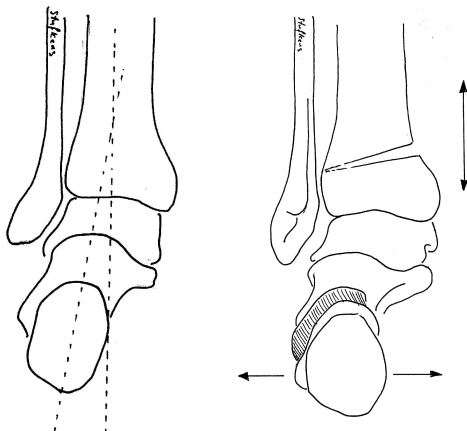
### Osteotomy

When?

- Asymmetric OA (Stages I-III)
- Symptomatic malalignment

Where?

Should place the correction at the Centre of Rotation of Angulation (CORA)



- Supramalleolar Osteotomy – Deformities above the ankle
- Calcaneal-Osteotomy – Deformities below the ankle joint

### How?

Opening or closing wedge supramalleolar osteotomy.

- Medial opening wedge easier to perform
- Lateral closing wedge often better for larger deformities
- Can correct in multiple planes
- Accurate preoperative assessment using 3D CT imaging
  - Can generate custom-built cutting jig for accurate bony cuts using 3D printer technology
- Flat cut or dome osteotomy may be used
  - Dome osteotomy for congruent joints

Calcaneal osteotomy (Medial column osteotomy)

### **Summary**

Risk for failure of supramalleolar osteotomy

- Large tilt- particularly varus (>7.3 degrees – Lee 2011)
- Advanced stages of OA – particularly medial gutter
- Significant instability
- Postop joint incongruence

### **References**

Knupp M, Stufkens SA, Bolliger L, Barg A, Hintermann B. Classification and treatment of supramalleolar deformities. *Foot Ankle Int.* 2011 Nov;32(11):1023-31.

Lee W-C, Moon J-S, Lee K, Byun WJ, Lee SH. Indications for Supramalleolar Osteotomy in Patients with Ankle Osteoarthritis and Varus Deformity. *J Bone Joint Surg Am*, 2011;93(13):1243 -1248.

---

## **Varus End Stage Ankle osteoarthritis – Senthil Kumar**

Options:

- Fusion
  - tibio-talar
  - tibio-talo-calcaneal
- Replacement

No specific criteria exist to help with the decision making process

**Fusion – Ankle** (Smith (2007): Open fusion in 25 ankles, 20 varus & 5 valgus (mean angles 26° & 28°), 24 ankles fused: Mean correction: 18 ankles: within 5° of neutral, 7 ankles: within 9° of neutral. Winson (2005): 105 fusions arthroscopic, Union rate of 92.5%, “an upper limit of 10-15 degrees of deformity is accepted”, “if the ankle deformity was of such a severe degree, the subtalar joint was often deformed or caused symptoms, which required a combined ankle and subtalar fusion”.

With longstanding deformities, the subtalar joint becomes abnormal (Hayashi 2008)

**Fusion – Tibio-Talo-Calcaneal (TTC) is used** Mainly for deformity corrections, non-union and neuropathic joints. Fusion rates of 67-100% often quoted – but does this mean of ankle, subtalar or both joints? Higgs (2013):61 fusions, 98% union at tibiotalar joint, 80% union at subtalar joint, full preparation of subtalar joint, removal of cross screw resulted in union

**Ankle replacement results are better in neutral alignment ankles**

- What is the cut off?
  - Wood and Deakin (2003): 15°
  - Wood et al (2010): 20°
  - Doets et al. (2006):10°

In a large series by Hobson et al (2009), total ankle replacements were performed in ankles with up to 10 degrees of deformity and compared with ankles with 11-30 degrees of deformity. There was no difference in the postoperative range of motion or complications between groups.

Some or all of the following may achieve correction of varus:

- Medial release of deltoid ligament from the tibia or talus +/- tib post lengthening
- Medial malleolar sliding osteotomy
- Debridement of lateral gutter
- Lateral ligament repair/reconstruction
- Calcaneal osteotomy
- 1<sup>st</sup> metatarsal osteotomy

## Summary

Both total ankle replacement and TTC remain good options for end stage varus ankle OA. When performing TAR in the presence of deformity, additional procedures must be carried out.

## References

- Doets HC, Brand R, Nelissen RG. Total ankle arthroplasty in inflammatory joint disease with use of two mobile-bearing designs. *J Bone Joint Surg Am.* 2006;88(6):1272-84.
- Hayashi K, Tanaka Y, Kumai T, Sugimoto K, Takakura Y. Correlation of compensatory alignment of the subtalar joint to the progression of primary osteoarthritis of the ankle. *Foot Ankle Int.* 2008;29(4):400-6.
- Hobson SA, Karantana A, Dhar S. Total ankle replacement in patients with significant pre operative deformity of the hind foot. *J Bone Joint Surg Br.* 2009;91:481-486.
- Higgs Z, Hooper G, Kumar CS. Incidence of symptomatic subtalar non union following tibiotalarcalcaneal arthrodesis using retrograde intramedullary nail. *Bone Joint J* 2013;95-B(SUPP 25):10.
- Smith R, Wood PL. Arthrodesis of the ankle in the presence of a large deformity in the coronal plane. *J Bone Joint Surg Br.* 2007;89(5):615-9.
- Wood PL, Karski MT, Watmough P. Total ankle replacement: the results of 100 mobility total ankle replacements. *J Bone Joint Surg Br.* 2010;92(7):958-62.

## Valgus End Stage Ankle arthritis – Jason Eyre

### Aetiology

Post traumatic (80%)

- Asymmetrical wear patterns e.g.
  - Mal-reduction of fracture
  - Ankle instability

Primary ankle arthritis (20%)

- Pes planus/tib post insufficiency

### Assessment

Look at gait and heel position on weight bearing. Assess for compensation and flexibility in the sub talar joint. Assess for deformity in the rest of the foot (planus etc.) and define clinically the degree of deformity and the range of motion in the ankle and sub talar joint.

Imaging should include weight bearing x ray and may include a hind foot alignment (Saltzman) or long leg alignment view. CT scan will reveal areas of bone loss and MRI will reveal the extent of joint surface damage and also damage to surrounding soft tissues. Ankle arthroscopy may be useful if joint preservation surgery is being considered.

### Management

Joint preservation

- Supramalleolar osteotomy
  - Restore alignment through ankle joint
  - May be opening lateral or closing medial wedge tibial osteotomy
- Hind foot/foot osteotomy and realignment
  - Calcaneal osteotomy
  - Midfoot plantar flexion osteotomy (Cotton)
  - Lateral column lengthening
  - Triple arthrodesis

Joint sacrifice

- Ankle fusion
  - Remains the “gold standard”
  - Arthroscopic or open
- Hindfoot fusion
  - Allows for correction through ankle and sub talar joint
  - Still must consider deformity in rest of foot
- Total ankle replacement
  - Requires careful balancing to avoid edge loading of prosthesis
  - Longevity remains an issue
  - Not a good option for young patients
  - Maximum deformity correction ?20 degrees

## Non-Insertional Achilles Tendinopathy Aetiology – Mike Karski

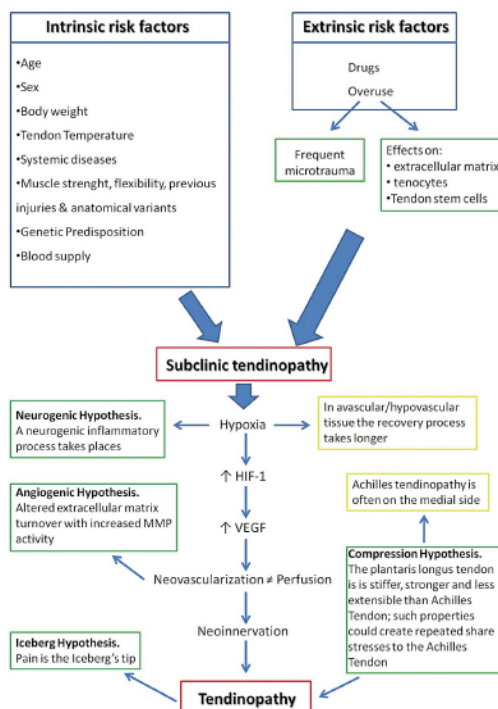
Maffulli (2004) proposed a histological definition with tendon degeneration not associated with inflammation. More recently pain and functional impairment have been added to the description (van Dijk 2011).

Histological appearances include: absence of inflammatory cells, poor healing response, collagen degeneration, vascular ingrowth, increased interfibrillar glycosaminoglycans, mucoid degeneration and lipid degeneration

The stress-strain curve relating to tendons was discussed, referencing the toe region, linear region prior to rupture. Repetitive trauma within the linear region causes the tendinopathy changes, followed by repair and re-injury.

The pathogenesis of achilles tendinopathy was discussed in a systematic review by Magnan (2014). Factors may be intrinsic (age, sex, body weight, tendon temperature, systemic disease, muscle strength/flexibility/previous injuries/anatomical variants, genetic predisposition, blood supply) and extrinsic (drugs, overuse). The risk factors predispose to sub clinic tendinopathy. Hypoxia is important in the angiogenesis hypothesis. Neo-innervation occurs, resulting in tendinopathy.

*B. Magnan et al./Foot and Ankle Surgery 20 (2014) 154–159*



The role of plantaris was discussed. In a cadaveric biomechanical study Lintz (2011) showed that plantaris is stringer and stiffer than the Achilles tendon. Potential differential movement between the two may trap peri-tendinous tissue medially between the plantaris and achilles.



Szaro (2009) demonstrated the origin of the Achilles fibres, showing 3 main fascicles in a twisted fashion which could function and be torn independently.

Alfredson (2003) showed that painful tendons had vasculo-neural ingrowth ventrally on ultrasound (with no vasculo-neural ingrowth in any of the pain free control group), with improved pain when local anaesthetic was injected.

Summary:

- Multiple extrinsic and intrinsic factors
- Histological changes are degenerative rather than inflammatory
- The role of plantaris is unclear
- Why tendinosis is painful is not fully understood.

References:

Alfredson H, Ohberg L, Forsgren S. Is vasculo-neural ingrowth the cause of pain in chronic Achilles tendinosis? An investigation using ultrasonography and colour Doppler, immunohistochemistry, and diagnostic injections. *Knee Surg Sports Traumatol Arthrosc.* 2003 Sep;11(5):334-8.

Maffulli N, Sharma P, Luscombe KL. Achilles tendinopathy: aetiology and management. *J R Soc Med.* 2004 Oct;97(10):472-6.

Magnan B, Bondi M, Pierantoni S, Samaila E. The pathogenesis of Achilles tendinopathy: a systematic review. *Foot Ankle Surg.* 2014 Sep;20(3):154-9.

van Dijk CN, van Sterkenburg MN, Wiegerinck JJ, Karlsson J, Maffulli N. Terminology for Achilles tendon related disorders. *Knee Surg Sports Traumatol Arthrosc.* 2011 May;19(5):835-41.

---

## Non-Insertional Achilles Tendinopathy Diagnosis – Melwyn Pereira

Diagnosis is clinical, based on pain, swelling and impaired performance. It may be associated with a tight gastrosoleus complex and “functional overpronation”. In Achilles tendinopathy, the mid-portion of the achilles is affected 2-6 cm proximal to the insertion. This accounts for 55-65% of Achilles tendon problems. Two percent are due to systemic causes.

Ultrasound is quick, safe and inexpensive. It is user-dependent. Classic findings are fusiform swelling, hypoechoic and hyperechogenic areas, with neovascularisation seen on doppler studies.

MRI is less user-dependent. It shows good visualisation of the tendon structure and contrast enhancement can show paratendinopathy. It cannot assess neovascularisation.

There is no strong evidence to identify on imaging who is at risk of rupture. Kainberger (1990) showed that mild early disease appeared normal on ultrasound, giving a better prognosis for early recovery. Astrom (1996) showed that MRI and ultrasound give similar information. False negatives on ultrasound were found to be milder with a better prognosis. Assessment of paratenon was unreliable in both. Khan (2003) concluded that imaging was not useful to monitor patient progress or determine readiness to return to sport. Clinical judgment is still required. Kannus (1991) found that all cases of a ruptured Achilles demonstrated histopathological changes (97% degenerative, 3% inflammatory or local tumours).

References:

Aström M, Gentz CF, Nilsson P, Rausing A, Sjöberg S, Westlin N. Imaging in chronic achilles tendinopathy: a comparison of ultrasonography, magnetic resonance imaging and surgical findings in 27 histologically verified cases. *Skeletal Radiol.* 1996 Oct;25(7):615-20.

Kannus P, Józsa L. Histopathological changes preceding spontaneous rupture of a tendon. A controlled study of 891 patients. *J Bone Joint Surg Am.* 1991 Dec;73(10):1507-25.

---

## **Non-Insertional Achilles Tendinopathy: Non-operative Management – Andy Goldberg**

Physiotherapy consists of eccentric exercises. Alfredson's protocol is well-described. In a systematic review eccentric exercises were found to be superior to wait-and-see in two RCTs. Alfredson (1998) reported that 82% of patients using eccentric exercises returned to normal activities at 12 weeks, compared with 36% who used concentric exercises, with sustained improvement at 12 months.

Shockwave therapy has conflicting but some good evidence. Rompe (2008, 2009) showed positive results. NICE recommends this should be used only as part of a formal audit or clinical study.

Low level laser therapy uses laser at low power (so not to cause temperature increases). There is sparse level 5 evidence.

High volume injections act as a surgical decompression, splitting the tendon from the paratenon. The rationale for using high-volume injections is to produce local mechanical effects causing neovessels and nerves to stretch, break or occlude. The evidence is sparse.

GTN patches have some evidence of efficacy on RCTs, one positive and one negative. Patients may experience headaches.

Autologous blood injections have sparse evidence. The rationale for using this is to introduce an assortment of growth factors to an area of tendinopathy. In an RCT of whole blood versus nothing, both groups had eccentric exercises and numbers were small (less than 40). Results were similar at 6 weeks, and slightly better for injection at 12 weeks. It is not NICE reviewed so should only be used in a clinical study or controlled audit.

Electrical stimulation techniques (iontophoresis) have not been shown to have any effect in chronic disease but there is some evidence of an effect in the earliest stages.

Like whole blood, PRP works through the theory of injecting vital growth factors. An RCT by de Vos (2010) showed no benefit over saline.

Overall, all interventions attempt to cause an inflammation-repair sequence. However, the pathological process is not inflammatory. This may explain why these interventions do not have strong evidence.

The role of stem cells (MSCs) as a regenerative approach is unclear and is under investigation. This has been used successfully by vets in horses. *In vitro*, MSCs have been shown to differentiate into tenocytes in many animals (rats, horses, rhesus macaque) and in humans. However there are no in-vivo evidence to demonstrate this unequivocally.

### **References:**

- Alfredson H, Pietilä T, Jonsson P, Lorentzon R. Heavy-load eccentric calf muscle training for the treatment of chronic Achilles tendinosis. *Am J Sports Med.* 1998 May-Jun;26(3):360-6.
- de Vos RJ, Weir A, van Schie HT, Bierma-Zeinstra SM, Verhaar JA, Weinans H, Tol JL. Platelet-rich plasma injection for chronic Achilles tendinopathy: a randomized controlled trial. *JAMA.* 2010 Jan 13;303(2):144-9.
- Rompe JD, Furia J, Maffulli N. Eccentric loading versus eccentric loading plus shock-wave treatment for midportion achilles tendinopathy: a randomized controlled trial. *Am J Sports Med.* 2009 Mar;37(3):463-70.
-

## Non-Insertional Achilles Tendinopathy Operative Management – Fred Robinson

After 3-6 months of non-operative treatment, significant numbers are still symptomatic. Surgical options include: debridement, anterior devascularisation, plantaris excision, calf release, excision and repair.

Kvist (1980) debrided 201 tendons followed by early mobilisation, with good/excellent results in 194. Scott (2008) and Testa (2002) showed good results from percutaneous tenotomy. Maffulli (2013) used USS guided percutaneous tenotomy with no signs of paratendinopathy. He showed 77% good or excellent results. Alfredson (2011) reviewed 125 cases of ventral scraping. No difference was seen in percutaneous or mini-open approach. Early mobilisation. 89% were satisfied. In a further study of those that failed this treatment, 5/7 showed the plantaris tendon as invaginated., Plantaris release showed improvement. Calder (2014) performed scarping and plantaris release on 32 elite athletes, with 69% satisfied. Maquirriain (2013) showed complete resolution of symptoms at 7 years postoperatively with endoscopic debridement and tenotomy.

Gastrocnemius recession has shown good pain relief, but weakening (Nawoczenski 2015). Gurdezi (2013) showed 66% satisfied at 2.5 years post-operatively, but better outcomes were seen for non-insertional rather than insertional tendinopathy. Maffulli (2015) show good results of PMGR in 18 patents at 54 months. Benazzo (2014) showed good results using soles fibre transfer.

FHL tendon transfer is well described. Schon (2013) reviewed 58 cases with reduced pain and better function at 2 years post-operatively. Deese (2015) describe good results with the use of Achilles allograft for chronic tendinosis.

The presenter summarised his current surgical practice. Patients undergo debridement with a gastrocnemius release if tight. In a limited number of cases, FHL transfer is used.

### References:

Calder JD, Freeman R, Pollock N. Plantaris excision in the treatment of non-insertional Achilles tendinopathy in elite athletes. Br J Sports Med. 2014 [Epub ahead of print]  
Gurdezi S, Kohls-Gatzoulis J, Solan MC. Results of proximal medial gastrocnemius release for Achilles tendinopathy. Foot Ankle Int. 2013 Oct;34(10):1364-9..  
Maquirriain J. Surgical treatment of chronic achilles tendinopathy: long-term results of the endoscopic technique. J Foot Ankle Surg. 2013 Jul-Aug;52(4):451-5.  
Schon LC, Shores JL, Faro FD, Vora AM, Camire LM, Guyton GP. Flexor hallucis longus tendon transfer in treatment of Achilles tendinosis. J Bone Joint Surg Am. 2013 Jan 2;95(1):54-60.  
Scott AT, Le IL, Easley ME. Surgical strategies: noninsertional Achilles tendinopathy. Foot Ankle Int. 2008 Jul;29(7):759-71.

---

## Non-Insertional Achilles Tendinopathy Consensus

There was a unanimous consensus that the pathology is non-inflammatory.

Who believes that pre-existing tendinopathy exists in cases of acute Achilles tendon rupture?

Always	0
Often	0
Rarely	30
Never	0

Who believes that pre-existing symptomatic tendinopathy leads to Achilles tendon rupture?

Always	0
Often	0
Rarely	30
Never	0

Who believes that gastrocnemius tightness is associated with non-insertional tendinopathy?

Always	0
Often	24
Rarely	6
Never	0

How do you investigate non-insertional tendinopathy on first presentation?

MRI	5
USS	18
Neither	7

Who uses an eccentric contraction physiotherapy regime?

Yes	30
No	0

Who uses steroid injection?

Yes	0
No	30

Who uses the following interventions:

ESWT

Yes	18
No	12 (mostly as not available in local NHS)

Laser therapy

Yes	0
No	30

High volume injections

Yes	8
No	22

GTN patches

Yes	3
No	27

Autologous whole blood injections

Yes	0
No	30

Iontophoresis

Yes	0
No	30

PRP

Yes	1
No	29

Stem Cells

Yes	1
No	29

Dry Needling

Yes	3
No	27

What techniques are used for debridement?

Open	28
Arthroscopic	2
Percutaneous	0

Who cuts the plantaris tendon?

Always	4
Never	10
No vote	16

How many patients per year are seen?

<10	0
>10	30

Numbers of achilles decompressions performed annually?

<1	6
<5	17
>5	6
>10	1

Who performs PMGR for Achilles tendinosis?

Isolated	7
Combined with Achilles decompression	0
Never perform	19
No vote	4

How many reconstruct with FHL routinely?

Yes	0
No	30

If the tendon was at threat, how many use FHL?

Yes	28
No	2

**Convened participants of the 2015 Round Table Meeting were:**

Tom Ball  
Stephen Bendall  
Carolyn Chadwick  
Callum Clark  
Robert Clayton  
Tim Clough  
Nick Cullen  
Raman Dega  
Sunil Dhar  
Jason Eyre  
Nick Geary  
Andy Goldberg  
Mark Herron  
Paul Hodgson  
Natasha Hossain  
Gillian Jackson  
Billy Jowett  
Mike Karski  
Markus Knupp  
Senthil Kumar  
Matt Morris  
Melwyn Pereira  
Hari Prem  
James Ritchie  
Fred Robinson  
Mark Rogers  
Bob Sharp  
Dishan Singh  
George Smith  
Rhys Thomas  
Philip Vaughan





Ortho Solutions Limited  
West Station Business Park  
Spital Road  
Maldon  
Essex CM9 6FF  
United Kingdom

T: +44 (0) 1621 843599  
F: +44 (0) 1621 858953  
E: [sales@orthosol.com](mailto:sales@orthosol.com)

[www.orthosolutions.com](http://www.orthosolutions.com)